

The European Examination in Core Cardiology (EECC)

Contents

Background	2
The EECC: What it is and how to prepare.....	2
What it is designed to do.....	2
How it fits in with cardiology training.....	2
What it looks like	3
Examination Software	4
How to Prepare	4
EECC: Sample Questions.....	5
Range of questions	10
How it has been developed and how it is delivered	11
Registering for the exam	11
Answers to Sample KBA Questions.....	12

Background

The European Examination in Core Cardiology (former European Examination in General Cardiology - EEGC) is a knowledge-based assessment for use as part of a formal training programme. It is designed to assess the application of knowledge of the core areas of cardiology that are set out in the ESC Core Curriculum for the Cardiologist. The EECC serves only one element of the assessment of trainees and sits alongside workplace-based techniques, logbooks, and other indications of professional development. It is intended for trainees approaching the end of their third year in a national training programme. Enrolment is managed by the candidate's national society.

The EECC: What it is and how to prepare

This document has been created to give candidates sitting the examination an overview of what it is for, how it fits into their training programme, what it will look like and how to prepare and register. There are also 10 illustrative sample questions.

What it is designed to do

The aim of the examination is to assess a trainee's understanding of the necessary knowledge components of the cardiology curriculum to a level appropriate for a newly appointed specialist. As indicated in the curriculum this knowledge will cover all aspects of cardiovascular medicine including 'basic' aspects of the 'advanced' curricular areas.

- The EECC is no more than an assessment of the core cardiology knowledge expected of a newly qualified specialist in cardiology.
- The EECC is only one component of the assessment strategy for trainee specialists in cardiology.
- The EECC is not an exit exam and not an assessment of overall competence.

How it fits in with cardiology training

The curriculum defines the necessary knowledge, skills and behaviours that need to be acquired in order to become a specialist in core cardiology.

The EECC is intended to be taken around the end of the third year of training. It is only one of the range of assessments that are employed to track the trainee's progress.

The examination is designed specifically to determine if a trainee has gained sufficient knowledge for specialist practice; the score should not be used to rank candidates or to determine their suitability for advanced training.

A satisfactory performance in the EECC is required before completion of training. Trainees who fail to achieve this standard on the first sitting should usually proceed with their training provided other elements of their performance are judged to be satisfactory. The EECC will be offered on an annual basis so that a trainee will, if necessary, have opportunities to re-sit the examination.

What it looks like

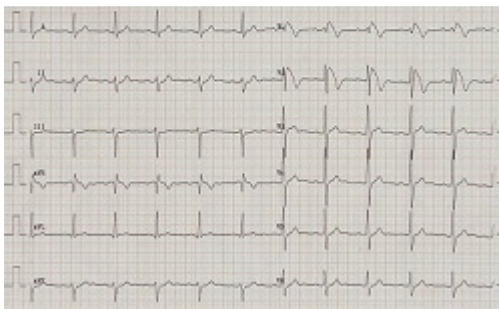
The examination consists of a single paper with 120 multiple choice questions (MCQs) to be answered in 3 hours. The questions consist of a clinical stem, possibly including reference to an image or video loop, followed by a single question and then a series of five choices of answer. The candidate must choose the best of the five options. There is no negative marking.

SAMPLE QUESTION:

Clinical stem:

A 39-year-old man presented to the emergency department with an episode of loss of consciousness whilst at a football match. He was being treated for hypertension but was otherwise fit and well. He was on treatment with bendroflumethiazide 5mg once daily and amlodipine 5mg once daily. On examination he was alert, had cold peripheries and his BP was 180/110 mmHg. His ECG is shown (see figure 1).

Figure:



Question:

What is the most likely diagnosis?

Five options:

- A. anterior STEMI
- B. aortic dissection
- C. Brugada syndrome
- D. hypokalaemia
- E. pulmonary embolism

The correct answer is C.

Examination Software

The examination software runs on individual PCs.

A short tutorial will be provided before commencement of the examination.

The screen has a timer showing how much time has elapsed. The question stem and the options appear on one screen. Any images or video loops will run in a separate window.

It is possible to flag questions as unanswered/uncertain to allow you to return to them later.

How to Prepare

ESC Core Curriculum for the Cardiologist aims to prepare trainees for a career in cardiology and to encourage development of the essential aptitude for lifelong learning. **There is no limited or exclusive list of appropriate sources of information.** Trainees are encouraged to **read extensively** and use the wide variety of available resources.

Examples of good sources of knowledge include:

- Textbooks e.g. [ESC General Cardiology Textbooks](#), including ESC Cardiomed
- Guidelines e.g. from ESC, AHA/ACC
- Educational articles e.g. [Education in Heart](#)
- On-line reviews e.g. theheart.org
- On-line educational material e.g. [ESC e-learning platform](#) ; ESC webinars and cases; Cardiosource,
- Academic journals e.g. [EHJ](#); Heart; NEJM; Lancet; Circulation; JACC
- ESC online preparatory modules:

EECC: Sample Questions

Please note that **these example questions are relatively easy** compared to the overall EECC and are provided only for illustrative purposes. As the question bank for the EECC is still relatively small in size it is not feasible to share past examination papers with candidates.

Please find the answers to the following ten sample EECC Questions at the end of this document.

1. A 56-year-old man was admitted for elective PCI to a complex bifurcation lesion in the mid-LAD. This was undertaken using conventional cardiac angiography equipment. To reduce his radiation exposure the operator moved from 50 cm away from the centre of the X-ray tube to 100cm away.

What is the best estimate of the % reduction of his radiation exposure?

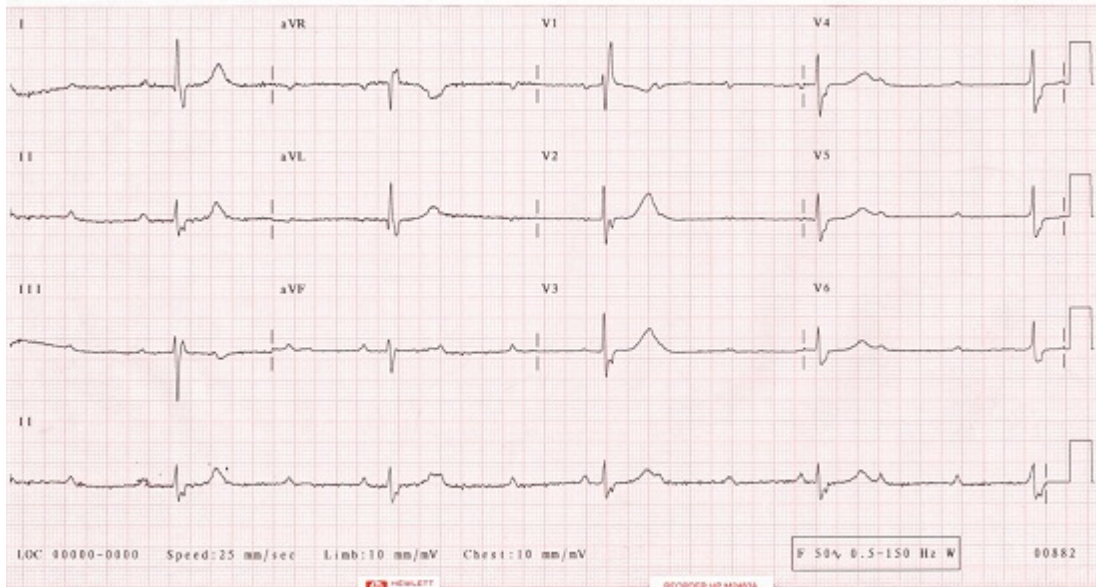
- A. 25%
- B. 50%
- C. 66%
- D. 75%
- E. 90%

2. A 60-year-old woman presented to the Emergency Department with a 3 week history of fatigue and episodes of pre-syncope. She was previously well and normally active. There was no significant past medical history.

Her ECG is as shown (see image).

What is the most appropriate treatment?

- A. dual chamber pacemaker in DDDR mode
- B. dual chamber pacemaker in DDIR mode
- C. single chamber pacemaker in AAIR mode
- D. single chamber pacemaker in VVI mode
- E. single chamber pacemaker in VVIR mode



3. A 25-year-old woman presented with recurrent syncope whilst exercising. She had no other cardiovascular symptoms or significant past medical history and took no regular medication. She was a non-smoker. Her aunt had died suddenly at the age of 32. There was no other family history of cardiovascular disease. Physical examination was normal.

Her ECG showed inverted T-waves in leads V1-V3, with a PR interval of 180ms and a QTc interval of 440ms. A 24-hour ECG recording revealed several episodes of non-sustained, regular broad complex tachycardia at 180-220 beats per minute with a left bundle branch block configuration. A transthoracic echocardiogram suggested a structurally normal heart but the images were reported to have limited endocardial definition.

What investigation is most likely to help in making the diagnosis?

- A. cardiac CT scan
- B. cardiac MRI scan
- C. contrast enhanced transthoracic echocardiogram
- D. right and left heart catheterisation with biopsy
- E. myocardial perfusion scan

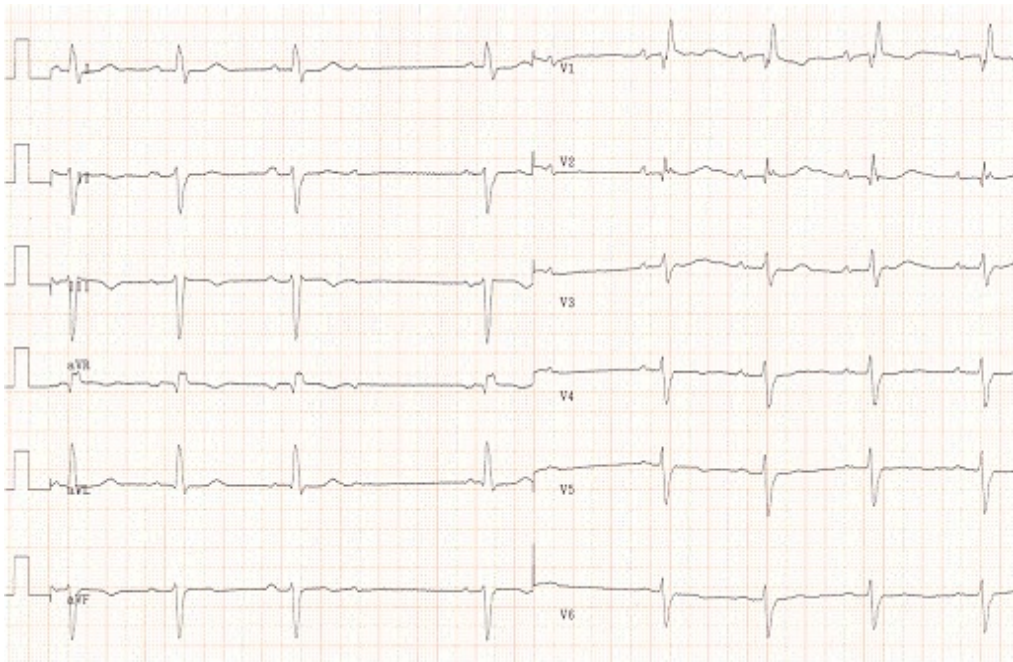
4. An 85-year-old woman presented with spells of dizziness during the previous 3 weeks. The episodes were not related to physical activity and she had no chest pain. She took no regular medication.

On examination her pulse was 40 beats per minute and irregular. Her blood pressure was 150/90 mmHg when supine and 135/80 mmHg when erect Physical examination was otherwise normal.

Her ECG is as shown (see image).

Which is the most likely cause of her dizziness?

- A. carotid sinus hypersensitivity
- B. intermittent high degree AV block
- C. orthostatic hypotension
- D. paroxysmal atrial fibrillation
- E. sinus node dysfunction



5. A 52-year-old man attended the out-patient clinic for review having been lost to follow-up for several years. He had a past history of aortic valve endocarditis 10 years earlier which had been successfully treated with antibiotics. He was asymptomatic but his family doctor had noted a murmur on routine examination.

On examination his pulse was 60 beats per minute and his blood pressure was 155/55mmHg. Auscultation revealed systolic and diastolic murmurs at the left sternal border. There was no clinical evidence of heart failure.

An echocardiogram revealed a left ventricular end-systolic dimension of 55mm, an end-diastolic dimension of 65mm, a left ventricular ejection fraction of 53% and an aortic root diameter 46mm. The aortic valve was bicuspid with severe regurgitation and a peak trans-valvular pressure gradient of 30 mmHg.

What is the most appropriate treatment at this stage?

- A. aortic valve and root replacement
- B. aortic valve replacement

- C. bisoprolol
 - D. no intervention required
 - E. ramipril
-

6. A 28-year-old man with Down's syndrome was seen in the Emergency Department complaining of breathlessness. On examination he had pitting oedema of his ankles and clubbing of his fingers and toes. The JVP was elevated to +7cm. He had a parasternal heave, a widely split second heart sound and a grade 2 systolic murmur loudest in the pulmonary area and at the left sternal border.

A transthoracic echocardiogram suggested an atrio-ventricular septal defect but imaging of the right heart was difficult and it was not possible to obtain an estimate of the right heart pressures.

What physical sign is most suggestive of pulmonary vascular disease?

- A. clubbing
 - B. elevated JVP
 - C. fixed splitting of second heart sound
 - D. parasternal heave
 - E. peripheral oedema
-

7. A 42-year-old man attended the Emergency Department of a small district hospital with a 60 minute history of central chest pain. On examination he was comfortable and there were no abnormal physical signs. His ECG showed an anterior myocardial infarct with ST elevation of >2mm in leads V2-V6, I and aVL. He had been given analgesia, 300mg of aspirin and 600mg of clopidogrel by the paramedical team en-route to hospital. There were no on-site facilities for PCI and emergency transfer was arranged to the regional heart attack centre which provided a 24/7 PCI service but had a transfer time of 90 minutes.

What is the most appropriate additional treatment to give whilst making arrangements for his transfer?

- A. bivalirudin
 - B. full dose fibrinolysis
 - C. glycoprotein IIb/IIIa receptor antagonist
 - D. glycoprotein IIb/IIIa receptor antagonist plus half dose fibrinolysis
 - E. half dose fibrinolysis
-

8. A 46-year-old man attended the Emergency Department with recurrent chest pain. He had attended 2 weeks earlier with a short history of fevers, generalised muscle aches including chest discomfort, shivers and mild diarrhoea. His ECG at that time had shown widespread concave upwards ST elevation and PR segment depression and he had been treated with ibuprofen 400 mg every 6 hours. His symptoms had settled and he had been discharged after 2 days feeling well and pain-free. Ibuprofen was stopped after 7 days. His chest pain had recurred on the day of his attendance.

On examination he had a pericardial rub. His ECG was unchanged.

What is the most appropriate treatment?

- A. azathioprine
 - B. ciclosporin
 - C. colchicine
 - D. ibuprofen
 - E. prednisolone
-

9. A 75-year-old man attended the Emergency Department with sudden onset of breathlessness and haemoptysis. He had a history of chronic obstructive pulmonary disease and had had an inguinal hernia repair two weeks previously.

On examination his pulse was 110 beats per minute in sinus rhythm and his blood pressure was 140/80 mmHg. The JVP was not raised and there was no ankle oedema. Chest auscultation revealed scanty wheeze. His peak expiratory flow rate was 290 L/min.

Pulmonary embolism was suspected.

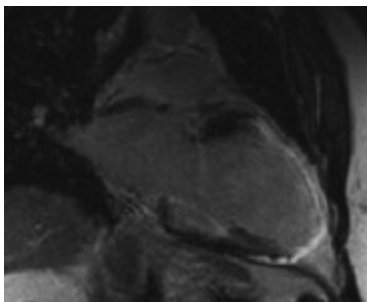
What is the most appropriate next investigation?

- A. CT pulmonary angiogram
 - B. d-dimer
 - C. invasive pulmonary angiography
 - D. venous Doppler ultrasound of the legs
 - E. ventilation-perfusion lung scan
-

10. A 57-year-old man was seen in the out-patient clinic with a 6 month history of progressive breathlessness. There was no significant past medical history. On examination he was obese and had mild ankle oedema but no other abnormal physical signs were identified. An ECG showed sinus rhythm with left bundle branch block. A chest X-ray revealed borderline cardiomegaly. Transthoracic echocardiographic images were non-diagnostic due to poor windows. A cardiac MR scan was performed (see image).

What is the most likely diagnosis?

- A. amyloid heart disease
- B. dilated cardiomyopathy
- C. haemochromatosis
- D. ischaemic heart disease
- E. sarcoidosis



Range of questions

Around 25% of questions will have an image or video i.e. the ratio of image/video questions to non-image questions will be approximately 1:3.

Valvular and Myocardial Disease will comprise approximately 20% of the questions

Valvular disease; Infective endocarditis; Myocardial Disease; Heart Failure

Ischaemic Heart Disease will comprise approximately 20% of the questions

Invasive cardiac imaging; cardiovascular Disease Protection i) risk factors iii) dyslipidaemia iv) diabetes; acute coronary syndromes; chronic IHD; rehabilitation and exercise physiology

Rhythm Disorders will comprise approximately 20% of the questions

Basic Investigations – ECG, ambulatory ECG, exercise testing; arrhythmias; atrial fibrillation; syncope; sudden cardiac death and resuscitation

Adult Congenital Heart Disease will comprise approximately 6% of the questions

Adult congenital heart disease; heart disease in pregnancy

Non-invasive Investigation will comprise approximately 14% of the questions

Non-invasive imaging including echocardiography - transthoracic, transoesophageal, stress echo; nuclear cardiology; cardiac MR; cardiac CT

Other “General Cardiology” will compromise approximately 20% of the questions

Clinical skills, history and examination; diseases of the aorta and trauma; peripheral vascular disease; pericardial disease; oncology and the heart; pulmonary hypertension; clinical genetics ; clinical pharmacology; cardiovascular disease protection ii) hypertension ; venous thrombo-embolism; the cardiac consult (Non-cardiac disease and the heart)

How it has been developed and how it is delivered

The EECC has been developed as a collaboration between the European Society of Cardiology, UEMS-Cardiac Section and the national societies.

The EECC is overseen by the EECC Board and is delivered online using CYIM/ProctorU® testing centres across Europe. There is a single sitting each year. There is no negative marking. The pass-mark is criterion referenced by a standard setting group which includes trainee representatives and is usually around 60% correct answers. The pass-rate is usually between 85-95% of candidates. Those who fail can re-sit the following year.

Registering for the exam

Registration usually starts in September and closes in April. The exam is open only to cardiology trainees in recognised training programmes in their third year of specialty training. It is the responsibility of the candidates to provide their national societies with the necessary information for registering them with Pearson Vue.

The current fee for taking the exam is determined by each national society.

In the event of illness please inform your national society as soon as possible.

You will be asked to fill in an online feedback form.

This information is used by the EECC Board to improve the exam and has proved, in the past, to be very helpful.

Answers to Sample KBA Questions

Question 1	D
Question 2	A
Question 3	B
Question 4	B
Question 5	E
Question 6	A
Question 7	A
Question 8	C
Question 9	A
Question 10	D